

Iodine-131 Metaiodobenzylguanidine for the Treatment of Neuroendocrine Tumors

a report by

R Edward Coleman, MD

Professor of Radiology, Duke University Medical Center

DOI: 10.17925/USE.2007.00.2.94

In the search for an imaging agent for the adrenal medulla, Wieland et al.¹ evaluated several guanethidine analogs. Although the iodobenzylguanidines (IBGs) radiolabeled in both the meta and para positions accumulated in the adrenal medullas of animals, the meta isomer (MIBG) demonstrated the best characteristics for imaging.² The radiolabeled MIBG was subsequently shown to be localized in pheochromocytoma,³ and other studies showed it to be highly accurate in identifying pheochromocytomas.⁴ Feldman et al.⁵ demonstrated that iodine (I)-131 MIBG accumulated in carcinoid tumors with a high sensitivity for detecting metastases from primary tumors in the ileum, but a low sensitivity for detecting pulmonary carcinoid tumors. Sisson et al.⁶ were the first to treat malignant pheochromocytoma with high doses of I-131 MIBG. Safford et al.^{7,8} demonstrated that higher initial doses of I-131 MIBG provided a better response to therapy in patients with pheochromocytoma, paraganglioma, and carcinoid tumor.^{7,8} MIBG imaging with either I-131 or I-123 and therapy with I-131 have been used to evaluate and treat several other types of neuroendocrine tumors, including neuroblastoma and medullary thyroid cancer. More recently, no-carrier-added radioiodinated MIBG has been shown to be superior to carrier-added radioiodinated MIBG in animal models and in imaging studies in patients.⁹⁻¹²

A clinical trial of a therapeutic form of no-carrier-added I-131 MIBG (Ultratrace™ Iobenguane I-131, Molecular Insight Pharmaceuticals Inc., Boston, MA) in patients with paraganglioma or metastatic pheochromocytoma has recently been embarked upon.

Mechanism of Accumulation

Because radioiodinated MIBG is an analog of adrenergic neuron blockers, it is accumulated by neuroendocrine tumors that have the noradrenaline

transporter.^{1,11} The MIBG enters the catecholamine storage vesicles of adrenergic nerve endings and cells in the adrenal medulla. Several studies have demonstrated that the accumulation of MIBG can be blocked or decreased by several drugs, including reserpine, tricyclic antidepressants, and labetalol.^{1,13} Alpha and beta adrenergic drugs do not interfere with the uptake of MIBG, except for labetalol, which inhibits amine uptake. Patients who are being considered for imaging or therapy with radioiodinated MIBG must not be taking any drugs competing with the accumulation of MIBG prior to its administration.

As a result of the high specific activity, the mass of the MIBG administered is much smaller using the Ultratrace methodology.

No-carrier-added I-131 Metaiodobenzylguanidine

The methodology for reducing high specific activity (no-carrier-added) I-131 was originally described in 1993, but has only recently been utilized.⁹⁻¹² The Ultratrace process uses a resin-exchange technology instead of the isotope-exchange methodology previously used. Prior to the development of no-carrier-added MIBG, only one in 2,000 molecules of MIBG contained I-131. With the Ultratrace Iobenguane, every molecule of MIBG contains I-131. As a result of the high specific activity, the mass of the MIBG administered is much smaller using the Ultratrace methodology. For the previously used methods of preparing I-131 MIBG, the mass of MIBG for a 1mCi diagnostic dose was approximately 0.3mg, and for a 350mCi therapeutic dose was 21mg. For a 350mCi dose prepared using the Ultratrace technology, the mass of MIBG is 0.039mg—i.e. approximately 1,000th of the amount of MIBG would be administered using the no-carrier-added preparation.

Previous Experience Using Therapeutic I-131 Metaiodobenzylguanidine

Between 1987 and 2006, 365 patients received 427 administrations of I-131 MIBG at Duke University Medical Center (DUMC). This MIBG had non-radioactive carrier present and was produced at the University of Michigan. These patients were treated under an investigational new drug (IND) license held by the University of Michigan and a physician-sponsored IND at DUMC. Of the 365 patients, 212 had carcinoid and 153



R Edward Coleman, MD, is Professor of Radiology, Vice Chair of the Department of Radiology, and Director of the Division of Nuclear Medicine at Duke University Medical Center (DUMC). He is a Fellow of the American College of Radiology (ACR) and the American College of Chest Physicians (ACCP). He was a founder and the first President of the Institute of Clinical Positron Emission Tomography (PET), a founder and second President of the Academy of Molecular Imaging (AMI), and is on the Board of Directors of

the AMI. In 2007 he received the prestigious Georg Charles de Hevesy Nuclear Pioneer Award from the Society of Nuclear Medicine. Dr Coleman has had several roles in the American Board of Nuclear Medicine (ABNM), the ACR, the Radiological Society of North America (RSNA), and the Society of Nuclear Medicine.

E: cole010@mc.duke.edu

had pheochromocytoma or paraganglioma. The maximum number of doses received by a single patient was six, and this was a patient who had malignant pheochromocytoma. The largest total dose administered to a single patient was 1.84Ci, administered over a period of four years.

When we first started performing MIBG therapy in 1987, we started with a dose of 136mCi. We gradually increased the amount of radioactivity, and by 1997 we were treating most patients with 500mCi. We noted that patients treated with doses greater than 500mCi experienced the expected hematological toxicity of prolonged leukopenia and thrombocytopenia. No long-term sequelae were identified. Fitzgerald et al.¹⁴ used a larger single dose with a median of 833mCi and range of 557–1185mCi for treating 30

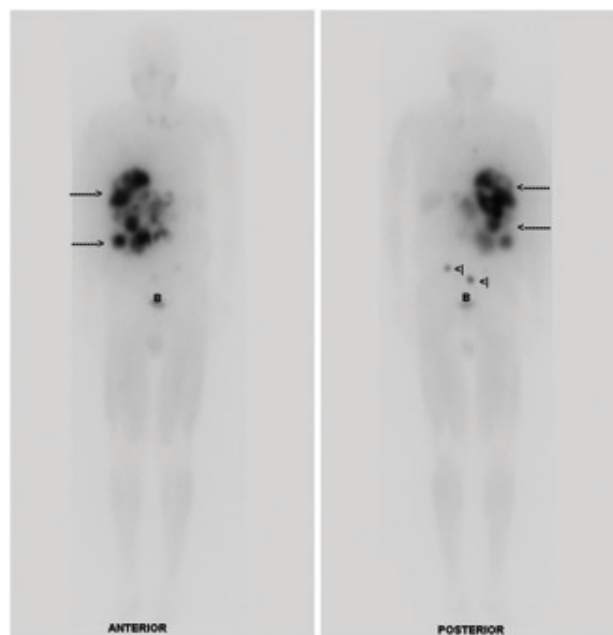
Patients who demonstrated a symptomatic response had a significantly longer median survival (5.8 years) than those who did not have a symptomatic response (2.1 years).

patients with malignant pheochromocytoma or paraganglioma. They collected peripheral blood stem cells prior to therapy. With the high-dose therapy, 19 patients received platelet transfusions, 19 patients received granulocyte colony stimulating factor, 12 patients received erythropoietin or red-blood-cell transfusions, and four patients needed the stem cells infused after therapy.

In a study of 98 patients with metastatic carcinoid tumor reported in 2004,⁸ 69 patients received one dose, 20 patients received two doses, and three patients received four doses. The mean (\pm standard deviation) administered dose was 401 \pm 202mCi. The major side effects seen with the therapy were pancytopenia in 10 patients, thrombocytopenia in three patients, and nausea/emesis in four patients. These patients recovered without sequelae. Two patients died soon after treatment, but the deaths were unrelated to the treatment. Significant decreases in urinary 5-hydroxy-indoleacetic acid (5-IHAA) levels were found after the MIBG therapy. Patients who demonstrated a symptomatic response had a significantly longer median survival (5.8 years) than those who did not have a symptomatic response (2.1 years). Furthermore, patients who initially received doses of greater than 400mCi had a significantly longer median survival (4.7 years) compared with 1.9 years in the patients who initially had a lower dose administered.

In a review of 33 patients treated with I-131 MIBG for metastatic pheochromocytoma (n=22) and paraganglioma (n=11), we determined that these patients received a mean dose of 388 \pm 131mCi. Those patients who had a symptomatic response had a significantly longer median survival (4.7 years) compared with 1.8 years for patients who did not have a symptomatic response. Patients who had a hormone response also demonstrated an increased survival compared with those with no hormone response (4.7 versus 2.6 years). Patients who received more than 500mCi as the initial therapy had an improved survival over those who had a lower initial dose (3.8 compared with 2.8 years).

Figure 1: A 63-year-old Man with Metastatic Pheochromocytoma



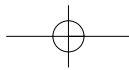
Anterior and posterior whole-body gamma camera images obtained seven days after treatment with 536 mCi of ultratrace iobenguane I-131. The study shows multiple hepatic metastases (arrows) and bony metastases in the pelvis (arrow heads). Normal bladder activity is noted in the low pelvis (B).

Safety, Distribution, and Radiation Dosimetry of No-carrier-added Iobenguane

The phase I study was performed in 11 patients for the evaluation of the safety, distribution, and radiation dosimetry of the Ultratrace iobenguane. The study was performed in seven patients with carcinoid tumor and four patients with metastatic pheochromocytoma. All patients had known I-131-MIBG-avid disease. The study was performed using

Patients who had a hormone response also demonstrated an increased survival compared with those with no hormone response (4.7 versus 2.6 years).

5mCi of Ultratrace iobenguane with a mass of MIBG that was equivalent to a 1Ci dose of Ultratrace iobenguane to ensure that the MIBG distribution determined on the imaging study would reflect that of the therapeutic dose. These patients had seven anterior and posterior whole-body images obtained over five days. Computed tomography (CT) scans were obtained and used to determine the volumes of the tumors in these patients. Regions of interest were drawn on the conjugate-view images, and geometric means computed for each source organ. A dosimetric analysis was performed by Radiation Dosimetry Systems, Inc.



Neuroendocrine Tumors

No side effects were noted with the administration of the Ultratrace iobenguane. The images demonstrated the known sites of disease in every patient. The largest organ dose was received by the thyroid, with a mean thyroid dose equal to $2.6 \pm 0.81 \text{ mGy/mBq}$ (mean \pm standard deviation). The only other organ with an estimated radiation dose exceeding 1.0 mGy/mBq was the salivary glands ($1.8 \pm 0.56 \text{ mGy/mBq}$). The radiation dose to the kidneys averaged $0.56 \pm 0.21 \text{ mGy/mBq}$. Some studies have suggested that 23 Gy would be a limiting radiation dose to the kidneys. The average maximum administered activity would be 45 gBq ($1,221 \text{ mCi}$) with a range from 21 to 58 gBq (581 to 1570 mCi). The computed tumor doses range from a low of 3.0 mGy/mBq (11 rad/mCi) to a high of 12 mGy/mBq (46 rad/mCi).

Phase I Study Evaluating the Maximum Tolerated Dose of Ultratrace Iobenguane I-131 (Azedra™)

A dose-escalation study is under way to determine the maximum tolerated dose in patients with malignant pheochromocytoma and paraganglioma. For this study, the patients meet several inclusion/exclusion criteria that include having at least one measurable lesion on CT that is also seen on Ultratrace iobenguane I-131 imaging (see *Figure 1*). Dosing began at 6.0 mCi/kg and was escalated in 1.0 mCi/kg increments. Patients have been treated at six, seven, and 8 mCi/kg , but not exceeding 450 , 525 , and 600 mCi , respectively. Images from the therapeutic dose are obtained one week after therapy, and they often show small-volume disease that was not seen on the pre-therapy scan.

A dose-escalation study is under way to determine the maximum tolerated dose in patients with malignant pheochromocytoma and paraganglioma.

The maximum tolerated dose will be the dose immediately below the level at which escalation stops due to dose-limiting toxicity. An additional three patients will be treated at the maximum tolerated dose for a total of six patients. Objective tumor response and biochemical response are assessed at three, six, nine, and 12 months, and semi-annually thereafter

for four years. After the phase I study is completed, the phase II study will be performed to determine the objective tumor response rate at nine months following therapy. At the time of this publication three patients have been treated at 6 mCi/kg and three patients at 7 mCi/kg in the phase I study. No dose-limiting toxicity was seen in these patients. Three patients have been treated at 8 mCi/kg and are being followed at this time.

The no-carrier-added Ultratrace iobenguane I-131 has advantages over the previously used carrier-added I-131 because of the higher specific activity.

During this dose-escalation study, most patients have demonstrated a decrease in their symptoms such as bone pain in patients who have bone metastatic disease and abdominal pain in patients with marked multiple large hepatic metastases. Decreases and normalization of chromogranin A levels, decreases in tumor markers, and significant decreases in volume of metastases have been seen in several patients as early as three months after therapy.

Conclusion

I-131 MIBG can be used to diagnose and treat neuroendocrine tumors such as paraganglioma and metastatic pheochromocytoma. The no-carrier-added Ultratrace iobenguane I-131 has advantages over the previously used carrier-added I-131 because of the higher specific activity. A phase I safety, imaging, and radiation dosimetry study of the Ultratrace iobenguane I-131 has shown no side effects of the radiopharmaceutical accumulation in sites of known paraganglioma and metastatic pheochromocytoma, and dosimetry calculations that demonstrate tolerable radiation doses to normal tissues and tumoricidal dose to tumor tissue when administered in therapeutic amounts. A dose-escalation study to determine maximum tolerated dose is near completion, and the maximum tolerated dose will likely be either 7 or 8 mCi/kg . The dose-limiting toxicity relates to the radiation effects on the bone marrow and manifests as leukopenia and thrombocytopenia. A phase II study to determine efficacy is planned to start in early 2008. ■

1. Wieland DM, Wu JL, Brown LE, et al., Radiolabeled adrenergic neuron blocking agents: adrenal medulla imaging with (131 I) iodobenzylguanidine, *J Nucl Med*, 1980;21:349–55.
2. Wieland DM, Brown LE, Tobes MC, et al., Imaging of the private adrenal medulla with (123I) and (131I) metaiodobenzylguanidine [concise communication], *J Nucl Med*, 1981;22:358–62.
3. Sisson JC, Frager MS, Valk TW, et al., Scintigraphic localization of pheochromocytoma, *N Engl J Med*, 1981;305:12–17.
4. Hanson MW, Feldman JM, Leight GS, et al., Iodine 131-labeled metaiodobenzylguanidine scintigraphy and biochemical analyses of pheochromocytomas, *Arch Int Med*, 1991;151:1397–1402.
5. Feldman JM, Blinder RA, Lucas KJ, et al., Iodine 131 metaiodobenzylguanidine scintigraphy of carcinoid tumors, *J Nucl Med*, 1986;27:1691–6.
6. Sisson JC, Shapiro B, Beierwaltes WH, et al., Radiopharmaceutical treatment of malignant pheochromocytoma, *J Nucl Med*, 1984;25:197–206.
7. Safford SD, Coleman RE, Gockerman JP, et al., Iodine-131 metaiodobenzylguanidine is an effective treatment for malignant pheochromocytoma and paraganglioma, *Surgery*, 2003;134:956–62.
8. Safford SD, Coleman RE, Gockerman JP, et al., Iodine-131 metaiodobenzylguanidine treatment for metastatic carcinoid. Results in 98 patients, *Cancer*, 2004;101:1987–93.
9. Vaidynathan G, Zalutsky MR, No-carrier-added synthesis of meta-[131I] iodobenzylguanidine, *Appl Radiat Isol*, 1993;44:621–8.
10. Fullerton NE, Boyd M, Ross SC, et al., Comparison of radiohaloanalogues of meta-iodobenzylguanidine (MIBG) for a combined gene- and targeted radiotherapy approach to bladder carcinoma, *Med Chem*, 2005;1:611–18.
11. Mairs RJ, Ross SC, McCluskey AG, et al., A transfectant mosaic xenograft model for evaluation of targeted radiotherapy in combination with gene therapy *in vivo*, *J Nucl Med*, 2007;48:1519–26.
12. Knickmeier M, Matheja P, Wichter T, et al., Clinical evaluation of no-carrier-added meta-[123I] iodobenzylguanidine for myocardial scintigraphy, *Eur J Nucl Med*, 2000;27:302–7.
13. Feldman JM, Frankel N, Coleman RE, Platelet uptake of the pheochromocytoma-scanning agent 131-I metaiodobenzylguanidine, *Metabolism*, 1984;33:397–9.
14. Fitzgerald PA, Goldsby RE, Huberty JP, et al., Malignant pheochromocytomas and paragangliomas: a phase II study of therapy with high-dose 131I-metaiodobenzylguanidine (131I-MIBG), *Ann N Y Acad Sci*, 2006;1073:465–90.

